

Facing the facts: Peri-implantitis management. Clinical outcomes based on sound periodontal surgical principles. Case report.



Andrés-García, R. DDS; Fernández-Farhall, J; Vadillo JM.



Department of Dentistry. San Rafael Hospital. Serrano 199. Madrid. 28035. Spain. +0034 670700997. randresgarcia@gmail.com

1

INTRODUCTION: Peri-implantitis can be defined as an inflammatory process surrounding an implant leading to loss of supporting bone fundamentally due to bacterial colonization of the implant surface. Treatment of the mentioned destructive process is decontamination of the affected area by debridement. At present there is no agreement on which is the best method for decontamination of the implant surface. Tetracycline, chlorhexidine, metronidazole, saline solution, citric acid, hydrogen peroxide or laser application have all been used but none of which has been proved to be the most effective.

The gold standard in the treatment of peri-implantitis is to achieve regeneration of deep infrabony defects, as well as re-osseointegration of the implant surface. The evidence of different animals and human studies suggest the possibility to achieve these objectives. Different methods have been evaluated as well as possible limiting factors. In the last decade, several protocols have been presented for the treatment of peri-implant lesions aiming to predict the highest possible rate of re-osseointegration, but there is still limited evidence regarding the most effective technique.

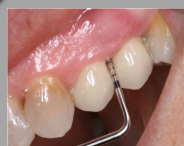2

OBJECTIVES: Regeneration of a 2-wall infraosseous defect produced by periimplantitis between two contiguous implants in the #24 and #25 location performed by surgical therapy trying to achieve re-osseointegration of the mentioned implants.

3

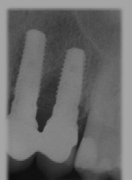CLINICAL SURGICAL PROCEDURE AND RESULTS

Periimplantitis

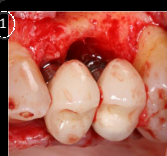

Probing depth 12 mm

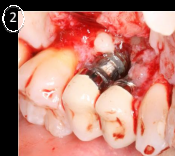
	23	24	25	26
V Rec	000	000	000	000
V PS	333	5511	1155	333
P Rec	000	000	000	000
P PS	333	555	523	333



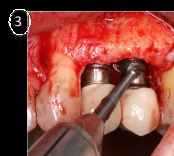
Surgical procedure



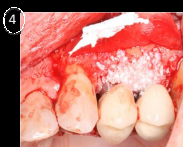Osseous defect



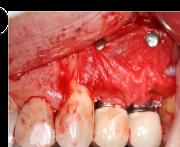Access to defect and implants



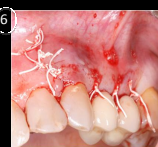Defect debridement
Decontamination of the implant
surface with tetracycline
(Vibramicine®)



Filling of the defect with
xenograft biomaterial (Bio-
Oss®)

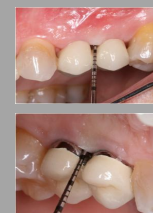

Collagen resorbable
membrane (Bio Guide®)

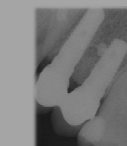


Sutures

24 months



	23	24	25	26
V Rec	000	000	000	000
V PS	332	233	333	323
P Rec	000	000	000	000
P PS	122	223	333	322



4

DISCUSSION: Surgical debridement, including implant surface decontamination, has proved to be more effective than closed therapy. In peri-implantitis lesions, non-surgical therapy was not found to be effective. Adjunctive chlorhexidine application had only limited effects on clinical and microbiological parameters. However, adjunctive local or systemic antibiotics were shown to reduce bleeding on probing and probing depths. No single method of implant surface decontamination (chemical agents, air abrasives and lasers) was found to be superior. The re-osseointegration of the diseased implant does not occur despite surgical access, only in the apical area of the defect (Grunder 1993) due to the formation of a connective tissue bond between bone and the regenerated bone (Persson 2001), although other studies such as the one by Alhag in 2007 obtained complete re-osseointegration after debridement and decontamination of the surface with citric acid, saline solution and hydrogen peroxide.

Better results have been obtained performing open flap surgeries combined with bone grafts and membranes for regenerative purposes. Behneke in 2000 achieves re-osseointegration with autologous bone grafts. Other authors do not find differences with or without resorbable membrane barriers (Roos-Jansäker 2007) or with e-PTFE membranes, with which post-surgical expositions were frequently encountered. Romeo (2007) suggests performing remodelling of the implant surface (implantoplasty), but in other studies (Schou 2003, Sennerby 2005 and Wetzel 1999) a higher degree of re-osseointegration was found with rough-surface implants compared to machined-surface implants. Minor beneficial effects of laser therapy on peri-implantitis have been shown (Deppe 2007); this approach needs to be further evaluated.

CONCLUSION: 24 months post-treatment, a reduction in the PPD of 8 mm, a complete radiographic resolution of the bone defect and negative BOP can be found, after surgical debridement, treatment of the implant surface with antibiotics and a GBR procedure.

5

REFERENCES

- Alhag M, Renvert S, Polyzos I, Claffey N. Re-osseointegration on rough implants surfaces previously coated with bacterial biofilm: an experimental study in the dog. *Clinical Oral Implant Research* 2007; 26: 182-187.
- Behneke A, Behneke N. Treatment of peri-implantitis defects with autogenous bone grafts: six months to 3 year results of a prospective study in 17 patients. *International Journal of Oral and Maxillofacial Implants* 2000; 15: 125-138.
- Claffey N, Claffey E, Polyzos I, Renvert S. Surgical treatment of peri-implantitis. *J Clin Periodontol* 2008; 35 (Suppl 8): 316-332.
- Deppe H, Herth H, Neff A. Conventional versus CO2 laser-assisted treatment of peri-implant defects with the concomitant use of pure-phase beta-tricalcium phosphate: a 5-year clinical report. *International Journal of Oral and Maxillofacial Implants* 2007; 22: 79-86.
- Grunder U, Hürzeler MB. Treatment of ligature-induced peri-implantitis using guided tissue regeneration: a clinical and histologic study in the Beagle dog. *International Journal of Oral and Maxillofacial Implants* 1993; 8: 282-293.
- Persson LG, Ericsson I, Berglundh T, Lindhe J. Osseointegration following treatment of peri-implantitis and replacement of implant components. An experimental study in the dog. *Journal of Clinical Periodontology* 2001; 28: 258-263.
- Romeo E, Lopp D, Chinapasco M, Ghisolfi M, Vogel G. Therapy of peri-implantitis with resective surgery. A 3-year clinical trial on rough screw-shaped oral implants. Part II: radiographic outcome. *Clinical Oral Implants Research* 2007; 18: 179-187.
- Roos-Jansäker AM, Renvert H, Lindahl C, Renvert S. Surgical treatment of peri-implantitis using a bone substitute with or without a resorbable membrane: a prospective cohort study. *Journal of Clinical Periodontology* 2007; 34: 625-632.
- Schou S, Holmström P, Jørgensen T, Skovgaard LT, Slotte K. Implant surface preparation in the surgical treatment of experimental peri-implantitis with autogenous bone graft and PTFE membrane in cynomolgus monkeys. *Clinical Oral Implants Research* 2003; 14: 412-422.
- Sennerby L, Persson LG, Berglundh T, Wennerberg A, Lindhe J. Implant stability during initiation and resolution of experimental peri-implantitis: an experimental study in the dog. *Clinical Implant Dentistry and Related Research* 2005; 7: 136-140.
- Wetzel AC, Vassiliu J, Caffesse RG, Hammerle CH, Lang NP. Attempts to obtain re-osseointegration following experimental peri-implantitis in dogs. *Clinical Oral Implant Research* 1999; 10: 111-119.

camlogfoundation

